

# Accessory cavitated uterine malformations (ACUMs): an unfamiliar cause of dysmenorrhoea

Thulasi Setty MBChB MRCOG,<sup>a\*</sup> Joel Naftalin MBChB MRCOG MD,<sup>b</sup> Davor Jurkovic FRCOG MD<sup>b</sup>

<sup>a</sup>Clinical Research Fellow in Gynaecology Ultrasound, Institute for Women's Health, University College Hospital, London, UK

<sup>b</sup>Consultant Gynaecologist, Institute for Women's Health, University College Hospital, London, UK

\*Correspondence: Thulasi Setty. Email: [thulasi.setty@nhs.net](mailto:thulasi.setty@nhs.net)

Accepted on 4 January 2021. Published online 18 January 2022.

## Key Content

- Accessory cavitated uterine malformations (ACUMs) are isolated cavitated lesions within the lateral aspect of the myometrium, inferior to the attachment of the round ligament.
- They are a rare Müllerian anomaly and are increasingly recognised as a cause for severe dysmenorrhoea and pelvic pain.
- ACUMs can be diagnosed with ultrasound and magnetic resonance imaging, where they appear as well-defined lesions with a central cavity containing haemorrhagic content, surrounded by a myometrial mantle. On histological examination, the cavity is lined by functional endometrial glands and stroma.
- Recognised treatments include hormonal suppression, destruction of the endometrial lining by alcohol sclerotherapy, or complete surgical excision, which has demonstrated curative results.

## Learning Objectives

- To know what ACUMs are and recognise them as a cause of dysmenorrhoea and pelvic pain.
- To be able to diagnose an ACUM with the use of ultrasound, MRI and histological findings if surgically excised.
- To be able to counsel patients with ACUMs on the different management options, including conservative, medical and surgery.

## Ethical issues

- All women with ACUMs are currently offered surgical excision, but is it appropriate to offer this, to patients as young as 13 years old, with no long-term data on the effect of surgery on future fertility?

**Keywords:** accessory cavitated uterine malformation (ACUMs) / dysmenorrhoea / juvenile cystic adenomyoma / Müllerian anomaly / painful periods

Please cite this paper as: Setty T, Naftalin J, Jurkovic D. Accessory cavitated uterine malformations (ACUMs): an unfamiliar cause of dysmenorrhoea. *The Obstetrician & Gynaecologist* 2022;24:40–9. <https://doi.org/10.1111/tog.12787>

## Introduction

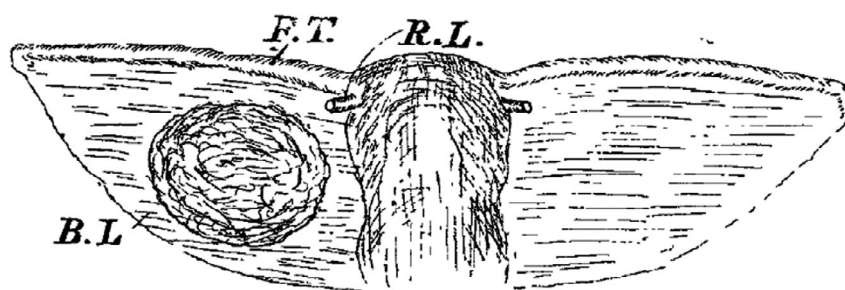
Accessory cavitated uterine malformations (ACUMs) are increasingly recognised myometrial lesions. They are considered a rare but significant cause of severe dysmenorrhoea, often in young women. ACUMs are isolated cavitated lesions located within the lateral aspect of the myometrium, inferior to the attachment of the round ligament of the uterus. They are considered to be of embryological origin.<sup>1</sup> The earliest description of an ACUM was by Oliver<sup>2</sup> in the early 20th Century: a patient presenting with dysmenorrhoea underwent surgical excision of a tumour from the broad ligament, which was described as “a globular-shaped closed sac, containing chocolate-coloured fluid, thick-walled and lined by cuboidal epithelium, which resembled very closely the stroma of normal endometrium” (Figure 1).<sup>2</sup>

Until 2010, there had only been occasional case reports in the literature describing this phenomenon. Then, Acien et al.<sup>1</sup> published a literature review of ACUMs alongside a

series of four of their own cases. In 2012, the same authors coined the term ‘ACUM’ to describe these lesions, which – until then – had no agreed name.<sup>3</sup> Subsequent advances in imaging have allowed more detailed examinations of uterine architecture – more specifically, the myometrium – thereby increasing visualisation of this important but relatively unknown pathology. This review summarises the existing literature on ACUMs, in particular demographics, clinical presentation, diagnostic imaging and available treatment options, to increase knowledge and aid better detection of ACUMs in everyday clinical practice.

## Epidemiology

Currently, the literature on ACUMs is limited to case reports and case series and there have been no formal prospective studies of the condition. The prevalence is therefore unknown, although, based on the scarcity of reported cases, it is probably a rare abnormality. Possible reasons for the paucity of evidence include poor recognition of the condition



**Figure 1.** A schematic demonstration of a uterus and ACUM within the right broad ligament from the original description published by Oliver et al. in the Lancet in 1912.<sup>(2)</sup> B.L = broad ligament; F.T. = fallopian tube; R.L. = round ligament.

among gynaecologists, radiologists and sonographers; variable quality of ultrasound, which remains the primary diagnostic tool in gynaecology; and challenges in reaching a diagnosis.

Some authors have proposed that ACUMs can only be diagnosed in women under the age of 30 years.<sup>3,4</sup> However, while 84% (78 out of 93 cases) of the reported cases are in women under the age of 30 years, there are published cases of ACUMs in older women.<sup>1–3,5–8</sup>

The literature reveals a preponderance of cases in Japan, with 16 out of 93 (17%) cases published by authors from Japan.<sup>4,9–14</sup> This probably reflects increased clinician awareness of the condition in Japan rather than a genuine increased prevalence of the condition within this population.

## Nomenclature

Various terms have been used to describe what we now call ‘ACUMs’. These include ‘juvenile cystic adenomyoma’,<sup>4,9,13–24</sup> ‘isolated cystic adenomyoma’,<sup>5,10–12,25,26</sup> ‘uterine-like mass’,<sup>27,28</sup> or ‘accessory uterine cavity’.<sup>2,29,30</sup> In 2010, Acién et al. reviewed the literature to determine how many published cases represented true ACUMs. Eighteen clinical cases met their proposed criteria, as outlined in Box 1.<sup>1</sup> Initially termed as an ‘accessory cavitated uterine mass’,<sup>3</sup>

### Box 1. Diagnostic criteria of ACUMs

#### Location:

- Solitary lesion located in the lateral myometrium or broad ligament
- No communication with uterine cavity or fallopian tubes

#### Morphology:

- A cavitated lesion containing functional endometrium surrounded by a myometrial mantle

#### Histology:

- Cavitated lesions filled with dark brown haemorrhagic content
- Lined with functional endometrium
- Myometrial mantle has concentric organisation of smooth muscle

other authors have expressed concern that the term ‘mass’ can have sinister connotations for patients. The term ‘malformation’ has been proposed as a more specific and appropriate alternative, which might avoid unnecessary worry for what is, in fact, a benign lesion.<sup>8</sup>

## Aetiology

It has been suggested that the early occurrence of pain symptoms after menarche is evidence that ACUMs are a congenital rather than acquired malformation.<sup>13</sup> While the precise origin of ACUMs remains uncertain, all authors agree that they represent a Müllerian duct abnormality.<sup>1,3</sup> There are two theories about how they develop: that they represent an isolated Müllerian duct malformation, or a dysfunction of the female gubernaculum.<sup>1</sup>

During the fifth and sixth weeks of embryological development, the genital system is indifferent and exists as two pairs of genital tracts: the mesonephric (Wolffian) ducts and paramesonephric (Müllerian) ducts. Absence of testosterone cause the Wolffian ducts to regress in female embryos. The Müllerian ducts persist, fuse at the caudal end and extend cranially with a central cavity, eventually forming a functional uterus.<sup>31</sup> The unfused lateral arms form the fallopian tubes.<sup>31</sup> Remnants of the Müllerian ducts can lead to congenital uterine anomalies, thus supporting the theory that the origin of ACUMs might be associated with the duplication and persistence of a Müllerian duct segment at the level of the attachment of the round ligament.<sup>1</sup>

The embryological female gubernaculum persists as the round ligament of the uterus.<sup>32</sup> Acién et al.<sup>32</sup> hypothesise that the female gubernaculum is probably formed by muscle fibres that are not derived from either the mesonephric or paramesonephric ducts. They believe the attachment of the gubernaculum to the Müllerian ducts induces the fusion and normal development of the uterus. The fact that all published cases of ACUMs describe their location in the insertion area or pathway of the round ligament substantiates this theory that ACUMs derive from maldevelopment of the gubernaculum.<sup>1,3,13,32,33</sup>

## Clinical presentation

Severe dysmenorrhoea is the commonest presenting symptom for women with ACUMs.<sup>3,7,12,13,15,23,34,35</sup> The pain can be central or ipsilateral to the side of the ACUM and may be accompanied by chronic pelvic pain.<sup>1,3,8,21,28,34</sup> The pain is thought to be caused by an accumulation of menstrual fluid from the functioning endometrium lining the ACUM within what is an enclosed space. This would lead to increased pressure within the ACUM and subsequent stretching of the cavity.<sup>3,9,13,19,26,27</sup> Pain often persists or even increases after the onset of menstruation.<sup>34</sup> Other symptoms reported by patients diagnosed with ACUMs include dyspareunia<sup>1,4</sup> and hypogastric pain,<sup>1,3</sup> although it is uncertain whether the ACUM was the primary cause of these symptoms. Currently, there are no descriptions of asymptomatic ACUMs in the literature. Potential reasons for this might include challenges to diagnosis, and the combination of a perceived requirement for histology to confirm diagnosis alongside the lack of an indication to excise an asymptomatic lesion. Nevertheless, asymptomatic ACUMs are feasible and future prospective observational studies might confirm that a proportion cause no pain. There are no published data to suggest that ACUMs are associated with menorrhagia or subfertility, and ACUMs have been diagnosed in parous women. Some authors have described a clinically palpable, tender mass on bimanual vaginal examination, which could be mistaken for a fibroid or ovarian cyst.<sup>1,13,25</sup>

## Investigations

### Ultrasound

Transvaginal ultrasound (TVUS) remains the first-line imaging tool in gynaecology, so it is particularly important to increase awareness of the ultrasound features of ACUMs. ACUMs appear on ultrasound as well-circumscribed, spherical, cavitated lesions, with a myometrial mantle and echogenic fluid content (Figure 2).<sup>8,24,36</sup> They are characteristically located in one of the lateral aspects of the anterior myometrium, inferior to the presumed insertion site of the round ligament.<sup>8</sup> The fluid content can either be 'ground glass' in nature, like the typical appearance on ultrasound of the contents of endometriomas, or hyperechoic.<sup>3,4,7,8,14</sup> The contents, being fluid, should be avascular on Doppler examination, and the blood flow in the myometrial mantle should be no different to the Doppler assessment of the surrounding myometrium.<sup>8</sup> ACUMs can be mistaken for obstructed congenital uterine anomalies, so two normal interstitial portions of the fallopian tubes must be visualised to confirm diagnosis. If TVUS is a relative or absolute contraindication, a transrectal ultrasound scan

(TRUS) is an acceptable alternative. This is usually well tolerated and has comparable image quality to TVUS.<sup>37</sup>

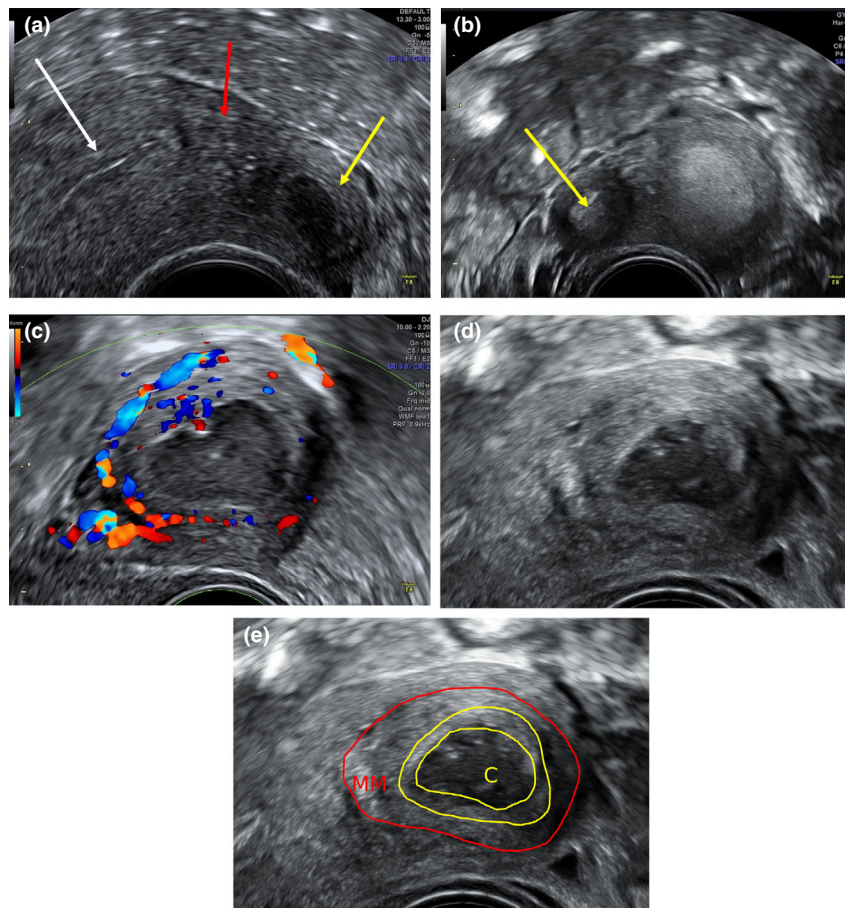
While some authors have described only requiring TVUS to make the diagnosis,<sup>8</sup> quality of ultrasound remains highly variable. This is reflected in the literature, where most authors routinely use additional imaging modalities to confirm the ACUM diagnosis.<sup>34,36</sup>

### Magnetic resonance imaging

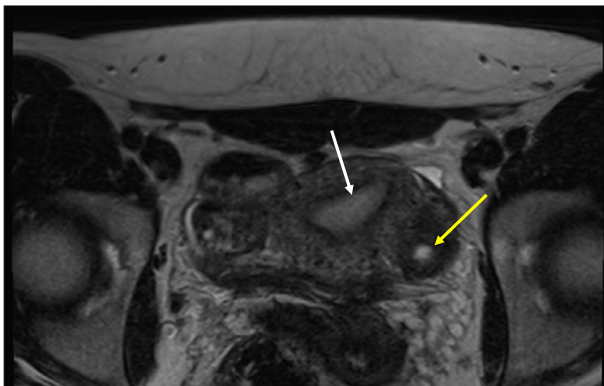
Most published case reports and cases series of ACUMs have been investigated using magnetic resonance imaging (MRI). MRI examinations include axial, coronal and sagittal T2-weighted turbo spin echo images, T1-weighted spin echo images and axial fat suppressed T1-weight images with 3–4-mm section thickness. This ensures exclusion of Müllerian anomalies by clearly visualising both cornua.<sup>34</sup> Peyron et al.<sup>34</sup> concluded that all ACUMs could be identified on MRI as 'a functioning and non-communicating accessory horn, present within the external myometrium or broad ligament in an otherwise normal uterus'. All ACUMs were found to have a central cavity, each surrounded by a well-defined ring with low T1 and T2 signal enhancements, which is similar to that of the junctional zone.<sup>34</sup> The surrounding cyst wall or myometrial mantle is seen as thickened and hypointense tissue on T2-weighted images, which demonstrates myometrial hypertrophy (Figure 3).<sup>26</sup> In addition, the cavities had a thin inner lining that moderately enhanced after gadolinium contrast and appeared hyperintense on T2-weighted images, indistinct from endometrium.<sup>34</sup> The internal content of the cavities displayed high T1 signal intensity, which remained after fat saturation and is indicative of haemorrhagic content.<sup>4,19,26,34,36</sup> Some lesions also displayed T2 shading, which is similarly seen with ovarian endometriomas, again confirming the haemorrhagic content of ACUMs.<sup>34</sup> All cases had normal uterine cavities and no concomitant uterine or renal tract anomalies.<sup>1,3,26,34,36</sup>

### Assessment of uterine morphology

Many authors have stated that an ACUM diagnosis can only be made in the presence of a normal uterine cavity and once an obstructive congenital uterine anomaly has been excluded.<sup>1,3,4</sup> Both hysterosalpingography (HSG) and hysteroscopy have been used to confirm a normal uterine cavity and fallopian tubes in this population.<sup>4,7,10,12,13,15,21,34,38</sup> Nevertheless, numerous other imaging modalities can be used to assess the uterine cavity, including 2D and 3D ultrasound, saline infusion sonohysterography (SIS), hysterosalpingo-contrast-sonography (HyCoSy), MRI, and laparoscopy and dye test.<sup>39,40</sup> Where there is no clear evidence to determine superiority of imaging modality, local preference will determine the choice.



**Figure 2.** Location and anatomy of ACUM. Transverse transvaginal ultrasound image of uterus and an ACUM in the left lateral myometrium (a). The ACUM (yellow arrow) can be seen lateral and inferior to the interstitial portion of the left fallopian tube (red arrow) and uterine cavity (white arrow). Note the echogenic contents of 'ground glass' appearance within the ACUM. (b) Hyperechoic cavity content within the ACUM (yellow arrow) on transverse transvaginal ultrasound image. (c) Transvaginal ultrasound image of a Doppler examination of an ACUM. Note the presence of vascularity within the myometrial mantle, but absence within the cavitated part of the lesion. The structure of an ACUM is illustrated in images (d) and (e), showing a central cavity 'C', hyperechoic internal lining – similar to that of endometrium (yellow border) and a surrounding myometrial mantle (MM, red border).



**Figure 3.** MRI of an ACUM. T2- weighted axial high-resolution MRI image showing the presence of an ACUM in the left lateral myometrium of the uterus (yellow arrow) with a normal uterine cavity (white arrow).

### Intraoperative diagnostic features

Diagnosis of an ACUM is rare and often delayed. There are documented cases of women with ACUMs undergoing numerous diagnostic laparoscopies to investigate symptoms of severe dysmenorrhoea and pelvic pain that failed to diagnose the ACUM.<sup>1,8,17,27</sup> ACUMs can be difficult to see and are **often missed** if not actively looked for, with the uterine contour being described as being entirely normal at laparoscopy or even during laparotomy in some cases.<sup>11</sup> In most cases, an ACUM appears as an **asymmetrical, often subtle enlargement on the right or left lateral aspect of the uterus, inferior to the insertion of the round ligament and classically contains altered blood, which appears as dark brown fluid.**<sup>1,3,8,15,34</sup> **Intraoperative ultrasound examination can successfully locate the ACUM and aid excision from the surrounding myometrium.**<sup>8,10,11</sup>



## Histology

Macroscopically, ACUMs have a 'uterus-like' organisation, with a central cavity lined by endometrium and surrounded by a myometrial mantle.<sup>13</sup> The largest case series to date<sup>8</sup> reported the mean outer cavity diameter of the ACUM to be 22.8 mm (95% confidence interval [CI] 20.9–24.8 mm) and the mean internal cavity diameter of the ACUMs to be 14.1 mm (95% CI 12.2–16.1 mm). These measurements are consistent with other studies reporting similar dimensions.<sup>4,34</sup>

Microscopically, the cavity is lined with glands and stroma, which positively stain for CD10, estrogen receptors (ER) and progesterone receptors (PR) – indicators of normal endometrial tissue.<sup>4,34</sup> Peyron et al.<sup>34</sup> describe a well-ordered concentric orientation of smooth muscle fibres in their surgically resected ACUM cases, which differentiates them from cystic adenomyosis, where the smooth fibres are more disordered.<sup>8</sup> Many authors report small foci of adenomyosis within the myometrial mantle.<sup>1,3,4,10,14,36</sup>

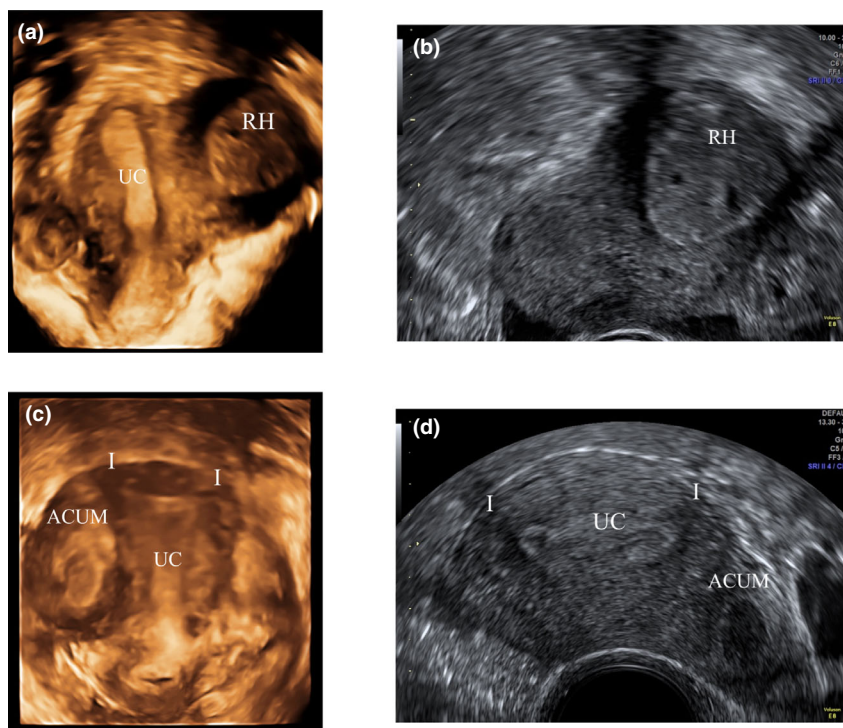
## Differential diagnoses

Diagnosing ACUMs can be challenging, primarily because there is unfamiliarity among clinicians, but also because of various differential diagnoses. Despite advances in imaging

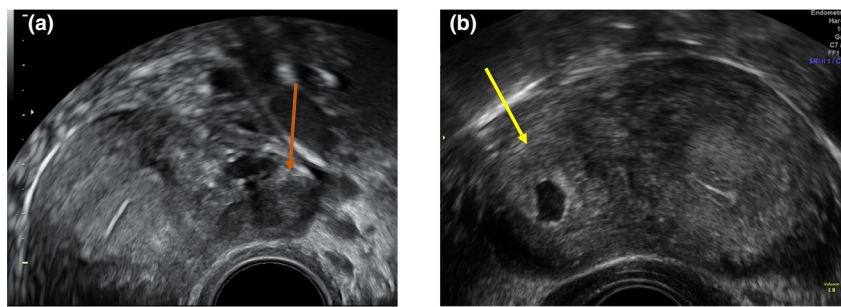
modalities such as high-resolution TVUS and pelvic MRI, it can be difficult to differentiate ACUMs from other more common pathologies. The presence of a morphologically normal uterine cavity is one defining feature of an ACUM.<sup>1,3,4,34</sup> This is to differentiate ACUMs from obstructive and non-obstructive congenital uterine anomalies, such as unicornuate uteri with a rudimentary horn (Figure 4), or Robert's uterus, which is defined as a septate uterus with a noncommunicating hemi-cavity.

ACUMs can be difficult to differentiate from fibroids located in the lateral aspect of the myometrium when they have altered central contents; for example, if they have undergone cystic, haemorrhagic or fatty degeneration (Figure 5).<sup>19,34</sup> However, central degeneration rarely occurs in fibroids of a similar size to ACUMs. Furthermore, fibroids that have undergone haemorrhagic degeneration can be distinguished from ACUMs on MRI, because accumulation of methaemoglobin in the obstructed veins at the periphery of a fibroid with haemorrhagic degeneration produces a rim that is hypointense in both T1- and T2-weighted images.<sup>19</sup>

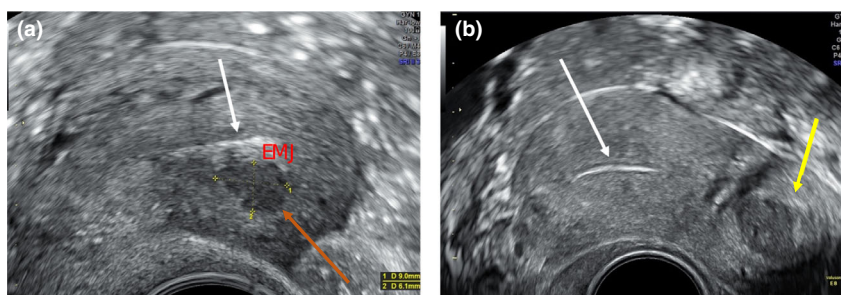
Up until 2010, many ACUMs were termed 'juvenile cystic adenomyomas' and treated as a rare form of adenomyosis. There are, however, features that distinguish ACUMs from true cystic adenomyomas, with regards to clinical



**Figure 4.** Differentiating an ACUM from a unicornuate uterus. These images demonstrate the difference between a unicornuate uterus with a functioning, non-communicating rudimentary horn and an ACUM. (a) A 3D-rendered coronal view of a right unicornuate uterine cavity (UC) with a functional, non-communicating rudimentary horn (RH) with haematometra secondary to obstructed outflow. This can also be seen on 2D transvaginal imaging (b). This is in contrast with a normally shaped uterine cavity with two interstitial portions (I) of the fallopian tube seen on a 3D rendered coronal view of the uterus containing an ACUM in the lateral myometrium (c) and on a 2D ultrasound transverse view of the uterus (d).



**Figure 5.** Differentiating an ACUM from a uterine fibroid. Transverse view of the uterus on transvaginal ultrasound sound showing a subserous fibroid on the left lateral aspect of the uterus (orange arrow in image (a)). In comparison to the ACUM in image (b) (yellow arrow), there is an absence of cavitation with a hyperechoic lining depicting endometrium and lack of myometrial mantle.



**Figure 6.** Differentiating an ACUM from a cavitating adenomyoma. This is a sagittal view of an anteverted uterus on transvaginal ultrasound scan demonstrating a cavitating adenomyoma in the anterior myometrium (orange arrow in image (a)). In comparison to the ACUM in image (b) (yellow arrow), there is a lack of myometrial mantle, it is contiguous with the endometrial-myometrial junction (EMJ) of uterine cavity (white arrow) and its location is in the central, anterior aspect of the uterus in contrast to the lateral location of the ACUM.

presentation, ultrasonographic appearance, surgical findings and histopathology (Figure 6, Table 1).<sup>1</sup>

**Congenital uterine cysts**, another differential diagnosis of ACUMs, are epithelial-lined myometrial cysts. Unlike ACUMs, they contain **simple fluid that appears anechoic on ultrasound, rather than blood, and their location within the myometrium is variable.** They also **lack a haemosiderin rim on histological examination, whereas ACUMs are lined with endometrium and have haemorrhagic content.**<sup>19,41</sup>

ACUMs can be mistaken for **ovarian endometriomas**,<sup>34</sup> particularly because endometriosis is a diagnosis actively sought in young women presenting with severe **dysmenorrhoea and pelvic pain.** An **endometrioma within an ovary adherent to the lateral aspect of the uterus** (a not uncommon finding in endometriosis), could easily be mistaken for an ACUM. There are, however, characteristic features to distinguish ovarian endometrioma, including the **presence of surrounding follicles within the ovarian cortex and the absence of a thick peripheral ring of muscular tissue** (Figure 7).<sup>34</sup>

## Treatment

### Expectant

Currently, all published research confirms the **benign nature of ACUMs** and, **in asymptomatic women,** they can be **managed expectantly.** However, the natural history of ACUMs is not known because most reported cases were managed by excisional surgery. Prospective observational studies are required to gain a greater understanding of the natural history of the condition.

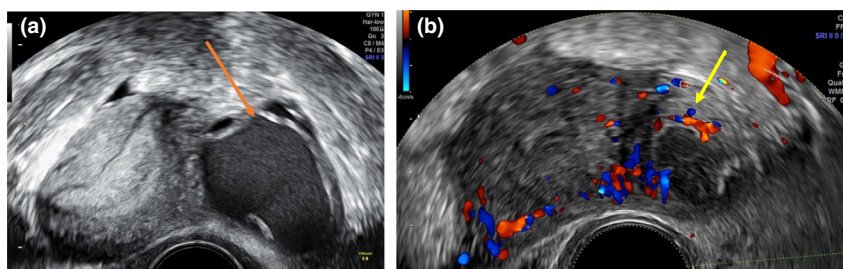
### Medical

Given that pain is the primary symptom of ACUMs, simple **analgesics such as nonsteroidal anti-inflammatory drugs (NSAIDs)** can be used. Many authors, however, describe these as being inadequate for controlling pain.<sup>4,13,15,17,21,34,38</sup>

The use of **suppressive hormonal treatments** have been described, including **continuous use of the oral contraceptive pill**,<sup>19,20,29,42</sup> **levonorgestrel-releasing intrauterine system (Mirena)**<sup>8</sup> or **gonadotrophin-releasing hormone (GnRH)**.<sup>4,10–13,20,24,34</sup> Naftalin et al.<sup>8</sup> found most patients

**Table 1.** Differences between ACUMs and true cystic adenomyomas.

Characteristics	ACUMs	True cystic adenomyoma
Demographics	Tend to affect younger, nulliparous women	Tends to affect older, multiparous women <sup>7</sup>
Clinical presentation	Severe menstrual pain and no association with heavy periods	Heavy, painful periods <sup>1</sup>
Concomitant pathology	Tend to be isolated lesions <sup>3</sup>	Usually found alongside other features of adenomyosis
Macroscopic histopathology findings	Distinct border between myometrial mantle and surrounding myometrium <sup>34</sup>	Irregular and poorly defined borders <sup>47</sup>
Microscopic histopathology findings	Concentric organisation of smooth muscle around cavity Endometrial glands and stroma seen to line cavity <sup>8</sup>	Surrounding myometrium lacks organisation Absence of internal epithelial lining of cystic cavity <sup>7</sup>
Location	In the lateral myometrium, inferior to the insertion of the round ligament and separate and distinct from the endometrial-myometrial junction <sup>34</sup>	Variable location within the myometrium, often within or contiguous with the endometrial-myometrial junction <sup>47</sup>



**Figure 7.** Differentiating an ACUM from an ovarian endometrioma. (a) Transverse view of a uterus with an enlarged left ovary adherent to the lateral aspect containing a unilocular cyst (orange arrow) with echogenic ‘ground glass’ content. The cyst is surrounded by normal ovarian tissue as illustrated by the presence of follicles. There is also an absence of a myometrial mantle as seen with an ACUM (yellow arrow) on image (b).

in their cohort wanted to avoid surgery in the first instance, with 10 out of 17 patients opting against primary surgery. Six of these patients chose hormonal treatments, with most achieving sufficient pain relief to defer or avoid surgery. ACUMs are often diagnosed in young teenage girls for whom surgery may not be the best primary treatment option. Branquinho<sup>19</sup> and Fissea<sup>42</sup> both describe teenage patients presenting with severe cyclical pelvic pain, who were found to have a cystic, haemorrhagic lesion within the lateral myometrium meeting diagnostic imaging criteria for an ACUM. They were both treated with continuous oral contraceptives, which achieved adequate pain relief at 6- and 12-month follow-ups.

Other authors have reported similar success with hormonal treatments, specifically the oral contraceptive pill and GnRH treatments. However, many patients experienced recurrence of symptoms when the treatment stopped.<sup>3,4,10–13,15,24,33,34,38</sup>

### Sclerotherapy

Reports on TVUS-guided aspiration and sclerotherapy for ovarian cysts, including endometriomas, have been published, with varied results.<sup>43,44</sup> Alcohol sclerotherapy can be an alternative to surgery, or be indicated where medical treatments have failed. However, with this approach, patients must be made aware it is not curative. They should also be counselled on the risks of symptom recurrence and the probable need for further intervention. It is, however, less invasive and does not carry the same risks as laparoscopy or laparotomy.

Sclerotherapy aims to destroy the cavity lining, resulting in inflammation and fibrosis with eventual obliteration.<sup>45</sup> Ethanol (95–99% concentration), in particular, has been shown to combine cytotoxic damage, hypertonic cellular dehydration and coagulation and thrombosis in the presence of blood products.<sup>45</sup> Naftalin et al.<sup>8</sup> used sclerotherapy as a primary treatment for ACUMs in four patients and described

**Box 2. Transvaginal sclerotherapy procedure for ACUMs**

- Perform under general anaesthetic
- Under continuous transvaginal ultrasound guidance, insert an 18-gauge needle through the anterior vaginal wall and myometrium, into the ACUM
- Aspirate intracavitary fluid (usually 2–3 mL) and send for cytological analysis
- Instil 99% ethanol into the cavity

reduced pain in the immediate follow-up. Two patients, however, later required surgical resection when pain resumed. Box 2 outlines the TVUS-guided sclerotherapy procedure for ACUMs. **Recognised risks of sclerotherapy include peritoneal leakage of the instilled alcohol; however, this is unlikely with ACUMs because the cavity is surrounded by myometrium.**<sup>44</sup>

There are currently no long-term follow-up data on the success of sclerotherapy of ACUMs. Data extrapolated from its use in the treatment of ovarian endometriomas suggests recurrence rates of 0–62.5% in a meta-analysis of 1102 patients over 15 studies with follow-up of 1–24 months. Rate of recurrence was largely influenced by the time of ethanol washing, with risk of cyst recurrence significantly higher in those with ethanol washings lasting less than 10 minutes.<sup>44</sup>

### Surgery

Nonsurgical treatments are important in the treatment of symptoms secondary to ACUMs, not least because they are less invasive and carry fewer risks than surgical excision. Nevertheless, most published cases of ACUMs have been treated surgically with high success rates. All published cases of surgery for ACUMs have reported almost **complete resolution of pain, with many patients remaining pain free until completion of follow-up.**<sup>1,3,4,8,34,38</sup> Excisions have been performed both **laparoscopically and by laparotomy.** Acien et al.<sup>1,3</sup> described performing a laparotomy for all eight of their cases up until 2012. The operations were either excision of the ACUM, or hysterectomy in those women with separate indications for hysterectomy. They described the advantage of open surgery as being greater surgical precision, allowing better enucleation of ACUMs that can have indistinct surgical planes.<sup>1,3</sup> Given that ACUMs are close to important structures such as the **uterine artery, urinary bladder and endometrial cavity, surgical precision of excision is of crucial importance.**<sup>33</sup> Other authors, however, showed that sufficiently precise enucleation of the ACUM can be also achieved at laparoscopy because of the image magnification and the use of fine dissection instruments. Combined with bidirectional blunt and sharp dissection, they achieved complete excision without spillage.<sup>33</sup> Laparoscopic enucleation of ACUMs has usually been favoured over

open surgery, for reasons including quicker recovery with reduced postoperative pain and the reduced incidence of adhesions.<sup>8</sup> However, this requires advanced laparoscopic skills, including the ability to suture laparoscopically. Nevertheless, with more hysterectomies and myomectomies being completed laparoscopically, more gynaecological surgeons should be sufficiently skilled to perform laparoscopic ACUM excision.

**Dividing the round ligament has been proposed as a means to clearly identify the ascending branch of the uterine artery to reduce the risk of inadvertent injury.**<sup>4,19,33,34</sup> **Dissection of the uterovesical fold has also been cited to facilitate safe access to the laterally placed ACUM.**<sup>33</sup> **Vasopressin infiltration into the uterine–ACUM serosal interface to aid with haemostasis** has been reported by almost all authors.<sup>4,6,7,10,11,13–17,38,46</sup> **The overlying serosa is incised with monopolar energy**<sup>4,6</sup> and **ACUM enucleation is performed in a circumferential manner along the ACUM–myometrial interface with the use of bipolar energy;** in contrast to a myomectomy, where dissection advances along a pseudocapsule.<sup>6</sup> If the boundaries of an ACUM are unclear, **intraoperative ultrasound has been described to facilitate delineation of the lesion and to aid excision.**<sup>8,13</sup> Intraoperative ultrasound can also help to **avoid inadvertent breach of the uterine cavity.** Peyron et al.<sup>34</sup> concluded that the mean distance of the ACUM from the uterine cavity was 6 mm on MRI, illustrating how easily a uterine cavity can be breached during surgical excision. While no studies have reported this complication, theoretical sequelae would include intrauterine adhesions, development of adenomyosis, and increased risk of future intrapartum uterine rupture. Authors have described intraoperative assessment of the integrity of the uterine cavity post-excision using methylene blue dye chromoperturbation.<sup>18,29,33,34</sup>

ACUMs are benign lesions, so there is no recognised danger in spillage of the ACUM contents. They rarely exceed 35 mm in mean diameter. Various techniques have been described for specimen retrieval, including the use of colpotomy,<sup>4</sup> morcellation<sup>10,15,23,46</sup> and specimen retrieval bags.<sup>7,8,16,33</sup>

### Follow-up

There is currently limited evidence to guide us on appropriate follow-up of these patients. Both the natural history of ACUMs and the long-term impact of surgical excision remain unknown. Prospective longitudinal studies are therefore required to further our understanding on whether they change with time, what impact they have on pregnancy and whether surgical excision has longer term sequelae. Future research questions include how surgical resection may affect fertility or pregnancy outcomes, and whether a trial of labour is a safe option for these women.



## Ethical issues

Surgical excision is curative, so this approach is currently offered to all women diagnosed with this Müllerian abnormality. However, this raises the ethical question as to whether it is appropriate to offer a treatment option with no long-term data on future fertility. This condition has been shown to affect patients as young as 13 years of age, so surgery as first-line treatment may not be suitable.

## Conclusion

ACUMs are an underdiagnosed Müllerian anomaly in women with refractory dysmenorrhoea. Further work is required to establish the true prevalence of ACUMs within the population, their long-term effects on women's health, and to carry out comparative studies of different treatment options.

## Disclosure of interests

There are no conflicts of interest.

## Contribution to authorship

TS researched and wrote the article. JN instigated and edited the article. DJ edited the article. All authors approved final version of the article.

## References

- 1 Ación P, Ación M, Fernández F, José Mayol M, Aranda I. The cavitated accessory uterine mass: a Müllerian anomaly in women with an otherwise normal uterus. *Obstet Gynecol* 2010;**116**:1101–9.
- 2 Oliver J. An accessory uterus distended with menstrual fluid enucleated from the substance of the right broad ligament. *Lancet* 1912;**179**:1609 [https://doi.org/10.1016/S0140-6736(00)51005-8].
- 3 Ación P, Bataller A, Fernández F, Ación MI, Rodríguez JM, Mayol MJ. New cases of accessory and cavitated uterine masses (ACUM): a significant cause of severe dysmenorrhoea and recurrent pelvic pain in young women. *Hum Reprod* 2012;**27**:683–94.
- 4 Takeuchi H, Kitade M, Kikuchi I, Kumakiri J, Kuroda K, Jinushi M. Diagnosis, laparoscopic management, and histopathologic findings of juvenile cystic adenomyoma: a review of nine cases. *Fertil Steril* 2010;**94**:862–8.
- 5 Protopapas A, Milingos S, Markaki S, Loutradis D, Haidopoulos D, Sotiropoulou M, et al. Cystic uterine tumors. *Gynecol Obstet Invest* 2008;**65**:275–80.
- 6 Peters A, Rindos NB, Guido RS, Donnellan NM. Uterine-sparing laparoscopic resection of accessory cavitated uterine masses. *J Minim Invasive Gynecol* 2018;**25**:24–5.
- 7 Supermaniam S, Thye WL. Diagnosis and laparoscopic excision of accessory cavitated uterine mass in young women: two case reports. *Case Rep Womens Health* 2020;**26**:e00187.
- 8 Naftalin J, Bean E, Saridogan E, Barton-Smith P, Arora R, Jurkovic D. Imaging in gynecological disease: clinical and ultrasound characteristics of accessory cavitated uterine malformations. *Ultrasound Obstet Gynecol* 2021;**57**:821–8.
- 9 Tamura M, Fukaya T, Takaya R, Ip CW, Yajima A. Juvenile adenomyotic cyst of the corpus uteri with dysmenorrhoea. *Tohoku J Exp Med* 1996;**178**:339–44.
- 10 Nabeshima H, Murakami T, Terada Y, Noda T, Yaegashi N, Okamura K. Total laparoscopic surgery of cystic adenomyoma under hydroultrasonographic monitoring. *J Am Assoc Gynecol Laparosc* 2003;**10**:195–9.
- 11 Nabeshima H, Murakami T, Nishimoto M, Sugawara N, Sato N. Successful total laparoscopic cystic adenomyomectomy after unsuccessful open surgery using transtrocar ultrasonographic guiding. *J Minim Invasive Gynecol* 2008;**15**:227–30.
- 12 Kamio M, Taguchi S, Oki T, Tsuji T, Iwamoto I, Yoshinaga M, et al. Isolated adenomyotic cyst associated with severe dysmenorrhoea. *J Obstet Gynaecol Res* 2007;**33**:388–91.
- 13 Takeda A, Sakai K, Mitsui T, Nakamura H. Laparoscopic management of juvenile cystic adenomyoma of the uterus: report of two cases and review of the literature. *J Minim Invasive Gynecol* 2007;**14**:370–4.
- 14 Kumakiri J, Kikuchi I, Sogawa Y, Jinushi M, Aoki Y, Kitade M, et al. Single-incision laparoscopic surgery using an articulating monopolar for juvenile cystic adenomyoma. *Minim Invasive Ther Allied Technol* 2013;**22**:312–5.
- 15 Kriplani A, Mahey R, Agarwal N, Bhatla N, Yadav R, Singh MK. Laparoscopic management of juvenile cystic adenomyoma: four cases. *J Minim Invasive Gynecol* 2011;**18**:343–8.
- 16 Chun SS, Hong DG, Seong WJ, Choi MH, Lee TH. Juvenile cystic adenomyoma in a 19-year-old woman: a case report with a proposal for new diagnostic criteria. *J Laparoendosc Adv Surg Tech A* 2011;**21**:771–4.
- 17 Jain N, Goel S. Cystic adenomyoma simulates uterine malformation: a diagnostic dilemma: case report of two unusual cases. *J Hum Reprod Sci* 2012;**5**:285–8.
- 18 Cucinella G, Billone V, Pitruzzella I, Lo Monte AI, Palumbo VD, Perino A. Adenomyotic cyst in a 25-year-old woman: case report. *J Minim Invasive Gynecol* 2013;**20**:894–8.
- 19 Branquinho MM, Marques AL, Leite HB, Silva IS. Juvenile cystic adenomyoma. *BMJ Case Rep* 2012;**2012**:bcr2012007006.
- 20 Deblaere L, Froyman W, den Bosch TV, Rompuy A-SV, Kaijser J, Deprest J, et al. Juvenile cystic adenomyosis: a case report and review of the literature. *Australas J Ultrasound Med* 2019;**22**:295–300.
- 21 Dadhwal V, Sharma A, Khoiwai K. Juvenile cystic adenomyoma mimicking a uterine anomaly: a report of two cases. *Eurasian J Med* 2017;**49**:59–61.
- 22 Pabuccu EG, Seval M, Sonmezer M, Atabekoglu C. Laparoscopic management of juvenile cystic adenomyoma. *J Minim Invasive Gynecol* 2015;**22**:S141.
- 23 Strelec M, Banović M, Banović V, Sirovec A. Juvenile cystic adenomyoma mimicking a Mullerian uterine anomaly successfully treated by laparoscopic excision. *Int J Gynaecol Obstet* 2019;**146**:265–6.
- 24 Akar ME, Leezer KH, Yalcinkaya TM. Robot-assisted laparoscopic management of a case with juvenile cystic adenomyoma. *Fertil Steril* 2010;**94**:e55–7.
- 25 Wang J-H, Wu R-J, Xu K-H, Lin J. Single large cystic adenomyoma of the uterus after cornual pregnancy and curettage. *Fertil Steril* 2007;**88**:965–7.
- 26 Ho M-L, Raptis C, Hulett R, McAlister WH, Moran K, Bhalla S. Adenomyotic cyst of the uterus in an adolescent. *Pediatr Radiol* 2008;**38**:1239–42.
- 27 Liang Y-J, Hao Q, Wu Y-Z, Wu B. Uterus-like mass in the left broad ligament misdiagnosed as a malformation of the uterus: a case report of a rare condition and review of the literature. *Fertil Steril* 2010;**93**:1347.e13–6.
- 28 David C, Burette J, Duminil L, Bonneau S, Janvier A, Hoeffel C, et al. Uterus-like mass: a case report. *Eur J Obstet Gynecol Reprod Biol* 2019;**233**:162–3.
- 29 Potter DA, Schenken RS. Noncommunicating accessory uterine cavity. *Fertil Steril* 1998;**70**:1165–6.
- 30 Steinkampf MP, Manning MT, Dharia S, Burke KD. An accessory uterine cavity as a cause of pelvic pain. *Obstet Gynecol* 2004;**103**:1058–61.
- 31 Moore KL, Persaud T, Torchia M. *The developing human: clinically oriented embryology*. 9<sup>th</sup> ed. Philadelphia, PA: Elsevier Saunders; 2012. p. 265.
- 32 Ación P, Sánchez del Campo F, Mayol M-J, Ación M. The female gubernaculum: role in the embryology and development of the genital tract and in the possible genesis of malformations. *Eur J Obstet Gynecol Reprod Biol* 2011;**159**:426–32.
- 33 Bedaiwy MA, Henry DN, Elguero S, Pickett S, Greenfield M. Accessory and cavitated uterine mass with functional endometrium in an adolescent: diagnosis and laparoscopic excision technique. *J Pediatr Adolesc Gynecol* 2013;**26**:e89–91.
- 34 Peyron N, Jacquemier E, Charlot M, Devouassoux M, Raudrant D, Golfier F, et al. Accessory cavitated uterine mass: MRI features and surgical correlations of a rare but under-recognised entity. *Eur Radiol* 2019;**29**:1144–52.
- 35 Garofalo A, Alemanno MG, Sochirca O, Pilloni E, Garofalo G, Chiadò Fiorio Tin M, et al. Accessory and cavitated uterine mass in an adolescent with

- severe dysmenorrhoea: From the ultrasound diagnosis to surgical treatment. *J Obstet Gynaecol* 2017;**37**:259–61.
- 36 Jain N, Verma R. Imaging diagnosis of accessory and cavitated uterine mass, a rare mullerian anomaly. *Indian J Radiol Imaging* 2014;**24**: 178–81.
- 37 Timor-Tritsch IE, Monteagudo A, Rebarber A, Goldstein SR, Tsybal T. Transrectal scanning: an alternative when transvaginal scanning is not feasible. *Ultrasound Obstet Gynecol* 2003;**21**:473–9.
- 38 Paul PG, Chopade G, Das T, Dhivya N, Patil S, Thomas M. Accessory cavitated uterine mass: a rare cause of severe dysmenorrhea in young women. *J Minim Invasive Gynecol* 2015;**22**:1300–3.
- 39 Ludwin A, Pityński K, Ludwin I, Banas T, Knafel A. Two- and three-dimensional ultrasonography and sonohysterography versus hysteroscopy with laparoscopy in the differential diagnosis of septate, bicornuate, and arcuate uteri. *J Minim Invasive Gynecol* 2013;**20**:90–9.
- 40 Salim R, Jurkovic D. Assessing congenital uterine anomalies: the role of three-dimensional ultrasonography. *Best Pract Res Clin Obstet Gynaecol* 2004;**18**:29–36.
- 41 Brosens I, Gordts S, Habiba M, Benagiano G. Uterine cystic adenomyosis: a disease of younger women. *J Pediatr Adolesc Gynecol* 2015;**28**:420–6.
- 42 Fisseha S, Smith YR, Kumetz LM, Mueller GC, Hussain H, Quint EH. Cystic myometrial lesion in the uterus of an adolescent girl. *Fertil Steril* 2006;**86**:716–8.
- 43 Kafali H, Eser A, Duvan CI, Keskin E, Onaran YA. Recurrence of ovarian cyst after sclerotherapy. *Minerva Ginecol* 2011;**63**:19–24.
- 44 Cohen A, Almog B, Tulandi T. Sclerotherapy in the management of ovarian endometrioma: systematic review and meta-analysis. *Fertil Steril* 2017;**108**:117–24.e5.
- 45 Albanese G, Kondo KL. *Pharmacology of sclerotherapy*. *Semin Interv Radiol* 2010;**27**:391–9.
- 46 Panwar A, Davis AA, Lata K, Sharma S, Kriplani A. Laparoscopic management of accessory cavitated uterine mass: a report of two cases and review of literature. *J Gynecol Surg* 2020;**36** [<https://doi.org/10.1089/gyn.2020.0019>].
- 47 Bazot M, Deux JF, Dahbi N, Chopier J. Myometrium diseases. *J Radiol* 2001;**82**:1819–40.